

# Autoimmune hemolytic anemia due to mediastinal teratoma: A case report and review article

Maryam Ghazizadeh<sup>1</sup> | Mohammad Moini<sup>2</sup> | Matin Ghazizadeh<sup>3</sup> 

<sup>1</sup>Department of Hematology—Oncology, Shahid Modarres Hospital, Shahid Beheshti University of Medical Sciences, Tehran, Iran

<sup>2</sup>School of Medicine, Tehran University of Medical Sciences, Tehran, Iran

<sup>3</sup>Department of Otolaryngology, Head and Neck Surgery, Taleghani Hospital, Shahid Beheshti University of Medical Sciences, Tehran, Iran

## Correspondence

Mohammad Moini, School of Medicine, Tehran University of Medical Sciences, Northern Gate of The University, Poursina Avenue, Qods Street, Enqelab Square, Tehran 1985717413, Iran.  
Email: [mohammadmoini1384@gmail.com](mailto:mohammadmoini1384@gmail.com)

## Key Clinical Message

Autoimmune hemolytic anemia (AIHA) is a rare disease that is divided into primary and secondary types. In patients with AIHA we should consider mediastinal tumors as a serious cause. If such teratoma was found surgical removal of it is in order.

## Abstract

Autoimmune hemolytic anemia (AIHA) is a rare disease that is divided into primary and secondary types. The secondary type usually appears as a complication to some diseases such as chronic inflammatory diseases, systemic lupus erythematosus (SLE), and malignancies. A 26 years-old female with a chief complaint of weakness, fatigue, and exertional dyspnea is diagnosed with AIHA. Initially, medical steroid treatment appeared to be successful and the anemia improved, however, by weaning steroid dosage the disease relapsed. Eventually, surgical resection of the mediastinal teratoma lead to the hemolysis being treated successfully. In patients with AIHA we should consider mediastinal tumors as a serious cause. If such teratoma was found surgical removal of it is in order.

## KEYWORDS

anemia, autoimmune disease, hemolytic, mature, mediastinum, teratoma

## 1 | INTRODUCTION

Autoimmune hemolytic anemia (AIHA) is defined as the presence of autoantibodies directed against autologous red blood cells (RBCs). Eighty percent of patients with AIHA, present warm reactive immunoglobulin G (IgG) isotype antibodies on their red cells. These antibodies' activity maximizes at a body temperature of 37 C. AIHA is divided into primary and secondary types. In patients diagnosed with secondary AIHA, the disease may be associated with a variety of disorders in the immune system such as systemic lupus erythematosus

(SLE) and certain chronic inflammatory diseases like ulcerative colitis. AIHA can also be caused by malignancies. Hematologic malignancies including chronic lymphocytic leukemia and malignant lymphoma are known to be the possible causes of AIHA.<sup>1,2</sup> But there are also some case reports showing an association between AIHA and solid tumors.<sup>3</sup> By searching Pubmed, we found 52 published cases reporting this association. AIHA has been confirmed in patients with a wide variety of tumors like squamous cell carcinoma, adenocarcinoma, seminoma, renal cell carcinoma, and Kaposi sarcoma.<sup>4</sup> Also there have been a few case reports of

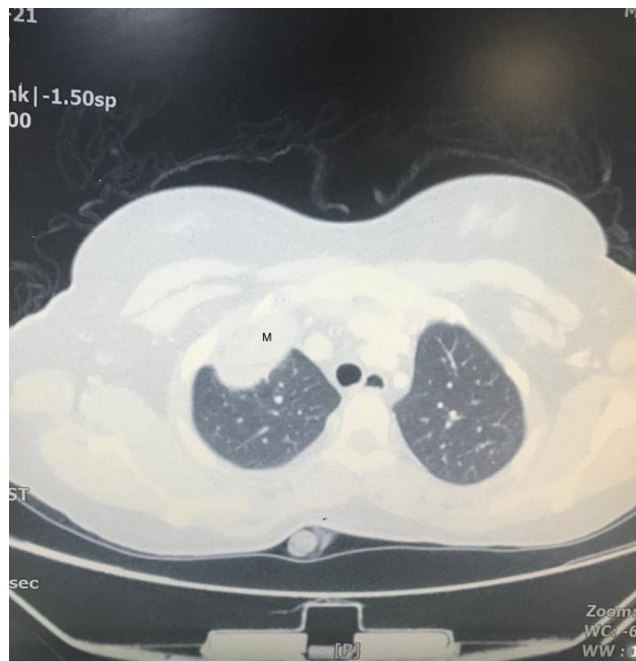This is an open access article under the terms of the [Creative Commons Attribution-NonCommercial-NoDerivs](https://creativecommons.org/licenses/by-nc-nd/4.0/) License, which permits use and distribution in any medium, provided the original work is properly cited, the use is non-commercial and no modifications or adaptations are made.

© 2023 The Authors. *Clinical Case Reports* published by John Wiley & Sons Ltd.

AIHA associated with ovarian dermoid cysts and ovarian mature cystic teratoma.<sup>5,6</sup> It is very rare for AIHA to be associated with mediastinal teratoma, therefore we were not able to find any similar case reports. In this article, we present a case of AIHA associated with mature cystic mediastinal teratoma.

## 2 | CASE REPORT

A 26 years-old female was referred with the chief complaint of weakness, fatigue, and exertional dyspnea. Her symptoms began 2 months ago. She had a past medical history of polycystic ovarian disease (PCO). There was no history of hypermenorrhea, blood transfusion, or gastrointestinal (GI) bleeding. She had a drug history of pantoprazole, folic acid, and medroxyprogesterone. Physical examination revealed conjunctival pallor and mild scleral icterus. The spleen and liver were normal in size. Her laboratory tests displayed hemoglobin of 9.6 g/dL, mean corpuscular volume (MCV) of 97.5 FL, reticulocyte count of 20%, and B12 and folic acid levels were normal. Additional tests presented lactate dehydrogenase (LDH) of 670 IU/L, total bilirubin of 2.5 mg/dL, and direct bilirubin of 0/5 mg/dL. The measured haptoglobin was 0.1 mg/dL and the erythrocyte sedimentation rate (ESR) was 26. Peripheral blood smear displayed anisocytosis and macrocytosis. Direct antiglobulin test (DAT) was positive for IgG, which showed warm consistency with AIHA. ANA, dsDNA, C3, C4, and CH50 were in the normal range. Alpha-Fetoprotein and Beta-HCG levels were normal as well. Also, the HIV test and viral markers were negative. A computed tomographic (CT) scan of the lung showed a mass in the right border of the mediastinum which measured 121 × 84 × 80 centimeters and was causing pressure effects on the right atrium and superior vena cava (SVC). (Figure 1) This mass consisted of some cystic fatty components with calcified walls. The CT scan shows a mediastinal mass compatible with teratoma, in the right mediastinum with expansion to the pericardium and the right hemi thorax. Echocardiography showed mild pericardial effusion and a large extracardiac mass around the right atrium. In the abdominopelvic sonography, the patient's spleen and liver were normal. A cystic structure with wall enhancement measuring 12 × 9 millimeters with little fat was seen in the left ovary. This cystic lesion was considered a recently ruptured follicle. Medical treatment with prednisolone was started to manage warm AIHA. Her hemoglobin level initially improved with prednisolone, however, after tapering the systemic steroid, its level decreased, and AIHA flared up. After consulting the thorax surgery department anterolateral thoracotomy



**FIGURE 1** Axial view of CT scan with contrast, showing a huge enhanced mass in the right anterior mediastinum (M represents mass).

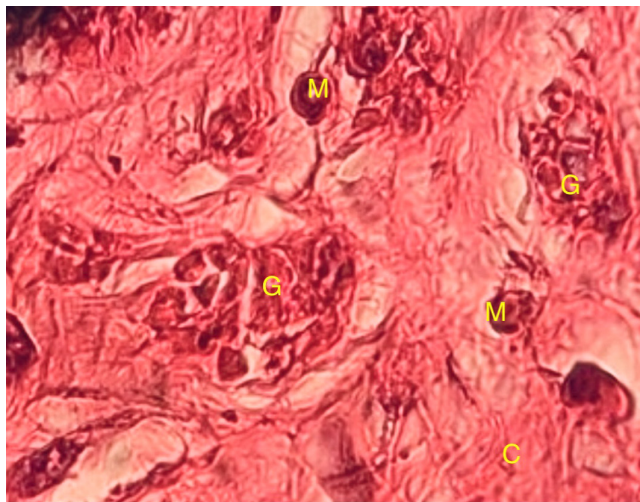
was performed resulting in perfect resection of the mediastinal mass. Up on histopathologic examination, the cyst contained cells derived from multiple origins that were well-matured and differentiated indicating a mature cystic teratoma. The pathologic feature was consistent with a cystic neoplasm with calcification of the wall, composed of intestinal tissue, cartilaginous tissue, stratified squamous epithelium, keratinous material, skin, sebaceous glands, and adnexal structures. Also, the endocervical lining, mature seromucous glands, and pancreatic and thymic tissues were present. Inflammatory reactions, foreign body granuloma, foamy macrophage infiltration, and fat necrosis were noted, too (Figure 2).

After the surgery hemoglobin levels gradually increased, also clinical and laboratory improvements of AIHA were obtained. The patient was followed up for 17 months postoperatively and the signs of AIHA did not reappear.

## 3 | DISCUSSION

AIHA is considered a rare disease with an incidence of 1 to 3 patients in 100,000 people per year.<sup>7</sup> Mostly the etiology is not clear, so it is called primary AIHA.<sup>8</sup>

The possible causes of secondary AIHA vary from medications to SLE, hematologic neoplasms, and solid tumors. However, teratoma has rarely been associated with AIHA. The relevance of hemolysis mechanisms



**FIGURE 2** Microscopic view showing the histopathology of teratoma. (M, G, and C represent foamy macrophage infiltration, foreign body granuloma, and cartilaginous tissue respectively).

and malignant tumors has not been defined completely. Some hypotheses suggested that cross-reactivity of tumor and RBC antigen, production of RBC autoantibodies by the tumor, or RBC molecules changes due to tumor, may play a contributing role regarding paraneoplastic AIHA.<sup>5,9</sup> Also there have been a few articles in which an association between AIHA and ovarian teratoma has been reported. In another case report, AIHA was accompanied by a mesenteric teratoma.<sup>10</sup> But we could not find any case reports demonstrating mediastinal teratoma as the underlying cause of AIHA, so this article seems to be the first case report regarding this issue. Teratomas are frequently localized in sacrococcygeal and gonadal regions, though, they can be localized in other areas such as the neck, mediastinum, retroperitoneum, nasopharynx, and maxillary regions.<sup>11</sup> Mediastinal teratoma is a type of germ cell tumor that is located in the anterior mediastinum and it accounts for 15% of anterior mediastinal masses. Mature teratoma of the mediastinum is usually benign and slow growing so these cases are usually asymptomatic. In symptomatic patients, the pressure effect causes pain, coughing, and dyspnea.<sup>12</sup> An association of hematologic disorders like immune thrombocytopenia and AIHA has been reported in ovarian teratoma, however, a hematologic disorder like AIHA in mediastinal teratoma is rare. Our case had AIHA and a huge mediastinal teratoma with invasions to the right atrium, SVC, and pericardium. Glucocorticoid is the preferred treatment for AIHA. In our case despite the initial response to steroid therapy, AIHA exacerbated after steroid tapering, so mediastinal tumor resection was performed. AIHA improved postoperatively and the patient remains asymptomatic until now. Thus, it

reveals that secondary AIHA occurred due to the patient's mediastinal teratoma.

## 4 | CONCLUSION

AIHA induced by mediastinal teratoma is very infrequent. Nevertheless, we should consider mediastinal tumors especially mediastinal teratomas in the differential diagnosis of secondary AIHA. The best treatment for teratoma-induced AIHA is surgical resection of the tumor.

## AUTHOR CONTRIBUTIONS

**Maryam Ghazizadeh:** Conceptualization; investigation; resources; visualization; writing – original draft. **Mohammad Moini:** Data curation; writing – original draft; writing – review and editing. **Matin Ghazizadeh:** Supervision; visualization; writing – review and editing.

## ACKNOWLEDGMENTS

None.

## FUNDING INFORMATION

No funding source has been used for the present article.

## CONFLICT OF INTEREST STATEMENT

The authors declare that they have no conflict of interest.

## DATA AVAILABILITY STATEMENT

The data that support the findings of this study are available on request from the corresponding author. The data are not publicly available due to privacy or ethical restrictions.

## CONSENT

Written informed consent was obtained from the patient to publish this report in accordance with the journal's patient consent policy.

## ORCID

Matin Ghazizadeh  <https://orcid.org/0000-0002-3755-3499>

## REFERENCES

1. Jung CK, Park JS, Lee EJ, et al. Autoimmune hemolytic anemia in a patient with primary ovarian non-Hodgkin's lymphoma. *J Korean Med Sci.* 2004;19(2):294-296.
2. Sallah S, Sigounas G, Vos P, Wan JY, Nguyen NP. Autoimmune hemolytic anemia in patients with non-Hodgkin's lymphoma: characteristics and significance. *Ann Oncol.* 2000;11(12):1571-1577.
3. Puthenparambil J, Lechner K, Kornek G. Autoimmune hemolytic anemia as a paraneoplastic phenomenon in solid tumors: a critical analysis of 52 cases reported in the literature. *Wien Klin Wochenschr.* 2010;122(7-8):229-236.

4. Spira MA, Lynch EC. Autoimmune hemolytic anemia and carcinoma: an unusual association. *Am J Med.* 1979;67(5):753-758.
5. Cobo F, Pereira A, Nomdedeu B, et al. Ovarian dermoid cyst-associated autoimmune hemolytic anemia: a case report with emphasis on pathogenic mechanisms. *Am J Clin Pathol.* 1996;105(5):567-571.
6. Kim I, Lee JY, Kwon JH, et al. A case of autoimmune hemolytic anemia associated with an ovarian teratoma. *J Korean Med Sci.* 2006;21(2):365-367.
7. Sokol RJ, Hewitt S, Stamps BK. Autoimmune hemolysis: an 18-year study of 865 cases referred to a regional transfusion center. *Br Med J (Clin Res Ed).* 1981;282(6281):2023-2027.
8. Hashimoto C. Autoimmune hemolytic anemia. *Clin Rev Allergy Immunol.* 1998;16(3):285-295.
9. Buonanno G, Gonnella F, Pettinato G, Castaldo C. Autoimmune hemolytic anemia and dermoid cyst of the mesentery A Case Report. *Cancer.* 1984;54(11):2533-2536.
10. Ntanishyan KI, Sabirov KR, Shcherbakova OV, Vybornykh DE, Shupletsova IA, Tsvetaeva NV. Autoimmune hemolytic anemia associated with mesenteric teratoma. *Ter Arkh.* 2017;89(1):78-81.
11. Tapper D, Lack EE. Teratomas in infancy and childhood. A 54-year experience at the Children's hospital medical center. *Ann Surg.* 1983;198(3):398-410.
12. No TH, Seol SH, Seo GW, et al. Benign mature teratoma in anterior mediastinum. *J Clin Med Res.* 2015;7(9):726-728.

**How to cite this article:** Ghazizadeh M, Moini M, Ghazizadeh M. Autoimmune hemolytic anemia due to mediastinal teratoma: A case report and review article. *Clin Case Rep.* 2023;11:e7908. doi:[10.1002/ccr3.7908](https://doi.org/10.1002/ccr3.7908)